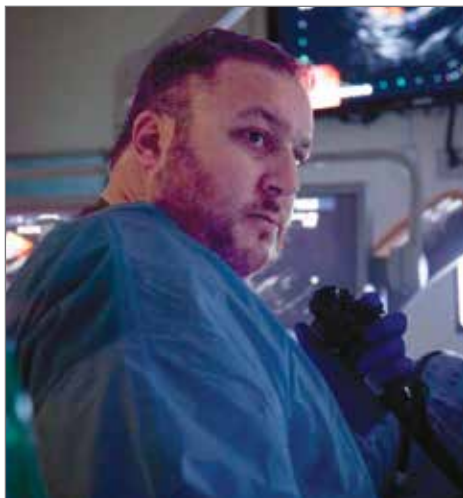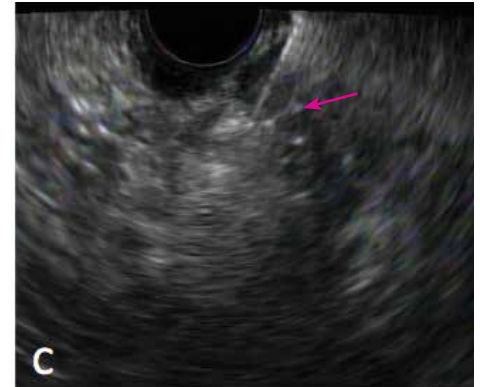

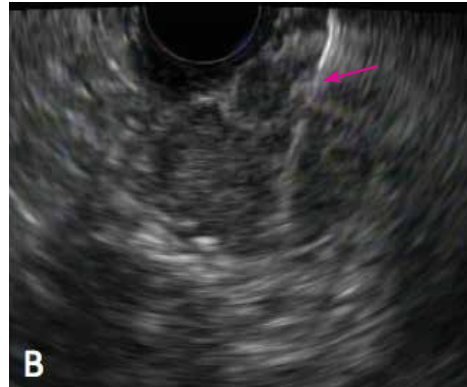
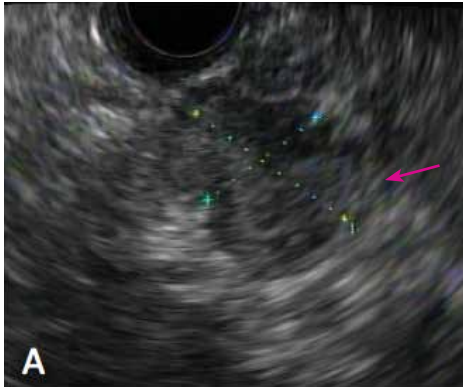Complex Insulinoma Case Avoids Complex Surgery



Christopher J. DiMaio, MD, Director of Therapeutic Endoscopy, and Associate Professor of Medicine (Gastroenterology)

EUS-guided ethanol ablation of a symptomatic pancreatic insulinoma. (A) Pancreatic insulinoma located in the pancreatic uncinate process. (B) Needle insertion into the mass. (C) Hyperechoic blush after injection of ethanol.

Doctors at Mount Sinai are expanding the way endoscopic ultrasound (EUS), a traditionally diagnostic tool, is used to treat complex cases by utilizing it as part of a therapeutic treatment option for select patients.

EUS is a powerful tool that allows for real-time evaluation of target organs and lesions in or around the gastrointestinal tract. Furthermore, EUS-guided needle biopsy has become the standard approach to diagnosing and staging GI neoplasms. Doctors at Mount Sinai, however, are using EUS-guided injection of ethanol directly into tumor targets as a quick and effective method of destroying tumor cells in select patients.

and lightheadedness, originally attributed to hypoglycemia, who was transferred to Mount Sinai from another hospital. The patient was seen initially by William B. Inabnet III, MD, Chair of Surgery at Mount Sinai Beth Israel and the Eugene W. Friedman Professor of Surgery at the Icahn School of Medicine at Mount Sinai, and Umur Sarpel, MD, Associate Professor of Surgery at the Icahn School of Medicine.

One such patient is an 86-year-old man who presented with intermittent weakness

A workup from the original hospital suggested an insulinoma, but imaging

continued on page 2 >

Mount Sinai Continues its Legacy of Firsts in Liver Transplant

Doctors at Mount Sinai have performed the first liver transplant in the United States for a patient with acute intermittent porphyria (AIP). The patient, Ms. Jennifer Long, was brought to The Mount Sinai Hospital for a liver transplant to save her from the debilitating disease.

AIP is one of several metabolic disorders caused by an enzymatic defect in the heme biosynthesis pathway. Partial deficiency of a

specific enzyme causes neurovisceral symptoms. An estimated one in 20,000 people carry the disease-causing genetic mutation, but only 20 percent of mutation carriers – including Ms. Long – will experience symptoms.

Over several years, Ms. Long's undiagnosed condition caused her constant pain and eventually led to a severe attack that left her paralyzed, forcing her to be hospitalized in her home state

continued on page 3 >

At the Forefront of Carcinoid Tumor Care

Faculty at The Mount Sinai Hospital are leading the fight against carcinoid tumors, and neuroendocrine tumors (NETs) in particular, being the first in the world to describe and offer a new surgical approach for the removal of previously inoperable NETs, and the first in the United States to employ the use of Gallium-68 in the NET detection process.

NETs are a set of relatively rare, slow-growing tumors that are complex to diagnose and treat, and predominantly affect the GI system. The Center for Carcinoid and Neuroendocrine Tumors at The Mount Sinai Hospital is one of only a few major centers in the United States able to diagnose, treat, and then study these complex tumors.

NETs are mostly considered a gastroenterology disease because the changed cells develop in the stomach, small intestine, appendix or colon, and then spread elsewhere through the blood, like any cancer. “The trick is to tell which tissue has the tumor,” says Celia M. Divino, MD, Stanley Edelman MD Professor of Surgery, and Chief of the Division of General Surgery at the Mount Sinai Health System. “It can be hard to tell the difference between the actual tumor and fibrous tissue that surrounds it.”

Dr. Divino and Richard Warner, MD, Professor of Medicine (Gastroenterology) at the Icahn School of Medicine at Mount Sinai (ISMMS), in collaboration with Michael Marin, MD, System Chair of Surgery and Dr. Julius H. Jacobson II Chair in Vascular Surgery at ISMMS, have developed a novel approach to treat unresectable carcinoid tumors called EVOTE (Endovascular Occlusion Tumor Excision), which uses a combined endovascular and surgical approach. They are the first in the world to describe and offer this unique approach to NET treatment.

GALLIUM-68 CLINICAL TRIAL

A clinical trial approved by the IRB is underway at Mount Sinai, to test the results of using Gallium-68 scanning to detect NETs. **Mount Sinai is the first health system in the United States to perform Gallium-68 scanning, which to date has only been used in Europe.**

The approach uses the gallium isotope to detect NETs, a much more sensitive technique than the commonly used Octreoscan. The gallium illuminates tiny tumors or metastasis quite prominently and has proven helpful in determining the extent of disease, assessing completeness of surgeries, and helping to determine treatment decisions.

Their EVOTE procedure uses a multidisciplinary approach to treatment that involves specialists in gastrointestinal (GI) and vascular surgery, GI medicine, and interventional radiology. A standardized protocol has been designed as part of the treatment plan, to increase the resectability rate of these tumors.

The approach involves the preoperative occlusion of the Superior Mesenteric Artery, or branch test, to determine adequacy of collateral flow. Patients who tolerate the occlusion then undergo endovascular embolization of the encased vessels, facilitating resection of the carcinoid tumor. This combined endovascular and surgical approach has been consistently successful in selected patients with unresectable tumors.

The Center receives referrals from all around the world, treating patients from Singapore, Pakistan, Moscow, and beyond. The team sees approximately 300 new cases per year plus follow up appointments from initial cases.

› Complex Insulinoma Case Avoids Complex Surgery *continued from page 1*

studies failed to identify or localize any lesion. Further imaging was performed at The Mount Sinai Hospital which revealed a 2.1 × 1.9 cm arterially enhancing mass within the uncinate process of the pancreas, most consistent with a neuroendocrine tumor (NET). Based on the patient’s serologic and imaging results, the suspicion was very high for a pancreatic insulinoma.

The case was presented and discussed at the weekly multidisciplinary GI Tumor Board meeting. Standard procedure calls for surgical resection, which in this case would require a pancreatico-duodenectomy (Whipple procedure). Given the patient’s history of cardiac and renal disease, however, he was deemed too high-risk for surgical intervention.

The GI endoscopy team at Mount Sinai, led by Christopher J. DiMaio, MD, Director of Therapeutic Endoscopy, and Associate Professor of Medicine (Gastroenterology), offered EUS-guided ethanol ablation as an alternative approach.

EUS was performed and a small mass lesion consistent with a pancreatic NET was identified. A 22-gauge EUS needle was inserted into the lesion, injecting small aliquots of ethanol (0.1 ml) throughout the mass with the hopes of destroying the insulin-producing tumor cells. The procedure was complete after approximately 30 minutes.

The following day, the patient was taken off IV dextrose infusion and IV steroids were not restarted. His blood glucose levels were

normal, he felt well without any symptoms of hypoglycemia, and he was discharged two days after the EUS procedure. He was completely asymptomatic one month after the surgery and remains so today.

Dr. DiMaio and his team continue to successfully perform the EUS procedure in patients with symptomatic pancreatic insulinomas, and they now also treat other lesions with this technique, including high-risk pancreatic cysts, and a solitary metastatic lymph node from a prior liver cancer.

Dr. DiMaio and colleagues have authored multiple publications describing the technical aspects of EUS-guided ethanol ablation, reporting on the feasibility, safety, and efficacy of the procedure.

of Maryland, for months at a time. Her appendix and gall bladder were removed but neither procedure helped.

More testing prompted family members to recall that Ms. Long's maternal uncle had suffered from porphyria. Ultimately, a genetic test revealed the cause of her pain: she suffered from AIP. Her primary doctor began a nationwide quest for porphyria expertise, ultimately turning to Robert Desnick, MD, PhD, Dean, Professor, and Chairman Emeritus of the Department of Genetics and Genomic Sciences at the Icahn School of Medicine at Mount Sinai.

Dr. Desnick asked two colleagues to consult on the case: Lawrence Liu, MD, Assistant Professor of Medicine (Liver Diseases) at Icahn School of Medicine; and Manisha Balwani, MBBS, Associate Professor, Genetics and Genomic Sciences, at Icahn School of Medicine. The team's expertise in both porphyria and liver transplant would prove exceptionally useful; Drs. Liu and Balwani see approximately 150 patients who receive combined care in the liver and porphyria specialties.

Dr. Liu had read accounts of successful liver transplants being done in the United Kingdom for patients with porphyria, but he knew that such a procedure had never been done in the United States.

He reviewed the outcomes and survival transplant data from AIP transplants done in the UK and presented his case at the weekly team meeting at The Recanati/Miller Transplantation Institute at Mount Sinai. He used the more commonly known enzyme defect seen in familial amyloid polyneuropathy (FAP) to help illustrate the rarer AIP for his colleagues and to emphasize the value of a liver transplant.



(l) Ms. Long pre-transplant; (r) Ms. Long six months after the transplant

"I explained that even though the porphyria DNA mutation would persist, Ms. Long's AIP enzyme defect was located in her liver, and the transplant procedure would stop her symptoms," recalls Dr. Liu. The team gave him a green light.

Due to the lack of precedent for liver transplantation in AIP patients in the United States, Ms. Long's case was also presented to the New York Transplant Regional Review Board who granted her 25 MELD points due to her exceptional circumstances. She was transferred from her local Maryland hospital to The Mount Sinai Hospital in January 2013 to await a new liver. Three months later, with an increased MELD score of 35 and porphyrin

levels 500 times above the normal range, Ms. Long underwent a successful deceased-donor liver transplant.

Following surgery, Ms. Long's porphyrin levels normalized within 24 hours. Before the liver transplant, she had required extremely high opiate doses via a patient-controlled analgesia pump but now takes only a small amount of hydromorphone for chronic nerve damage from AIP. She will never again experience the acute symptoms of porphyria which had so fiercely impeded her quality of life.

While Dr. Liu's team used best practices from the AIP liver transplants done in the UK, they also took the opportunity to research sections of the procedure that had not previously been studied. The team measured Ms. Long's porphyrin proteins every hour during and after the transplant using urine and blood samples, and analyzed her liver tissue to help identify factors that would explain the severity of her AIP. Their findings were recently published in *Mol Med* (2015; 21(1):487-95).

TOP RECRUIT

Patricia Sylla, MD

We are pleased to announce the arrival of Patricia Sylla, MD, as an Associate Professor in the Department of Surgery (Colorectal Surgery) at the Icahn School of Medicine at Mount Sinai.

Dr. Sylla comes to Mount Sinai from Massachusetts General Hospital in Boston, where she was an Assistant Professor of Surgery in the Division of Colon and Rectal Surgery, and where she continues to serve as a Visiting Scientist.



Patricia Sylla, MD

Clinically, Dr. Sylla specializes in minimally invasive approaches to colorectal diseases, with specific focus on endoscopy, laparoscopy and robotic surgery in the management of colon and rectal cancer, inflammatory bowel disease, diverticulitis and rectal prolapse.

Dr. Sylla's early research focused largely on developing a Natural Orifice Translumenal Endoscopic Surgery (NOTES) transanal approach to the colon and rectum in an experimental model. Based on this research, Dr. Sylla performed the first human transanal NOTES resection of a rectal cancer in November 2009. This led to the first IRB-approved pilot study of laparoscopy-assisted transanal endoscopic resection of rectal cancer in the United States, on which she was the principal investigator. Today, more than 500 cases of transanal total mesorectal resection have been published to date.

While at Mount Sinai, Dr. Sylla hopes to develop a multicenter phase II trial on the safety and efficacy of transanal endoscopic resection for rectal cancer.

Dr. Sylla obtained her medical degree from Weill Cornell Medical College in New York and completed her general surgery residency at Columbia Presbyterian Hospital. She completed a colorectal surgery fellowship at The Mount Sinai Hospital followed by a fellowship in minimally invasive surgery at Massachusetts General Hospital.

MULTIDISCIPLINARY CARE

Rare Chemo Alternative Obliterates Cancer Cells

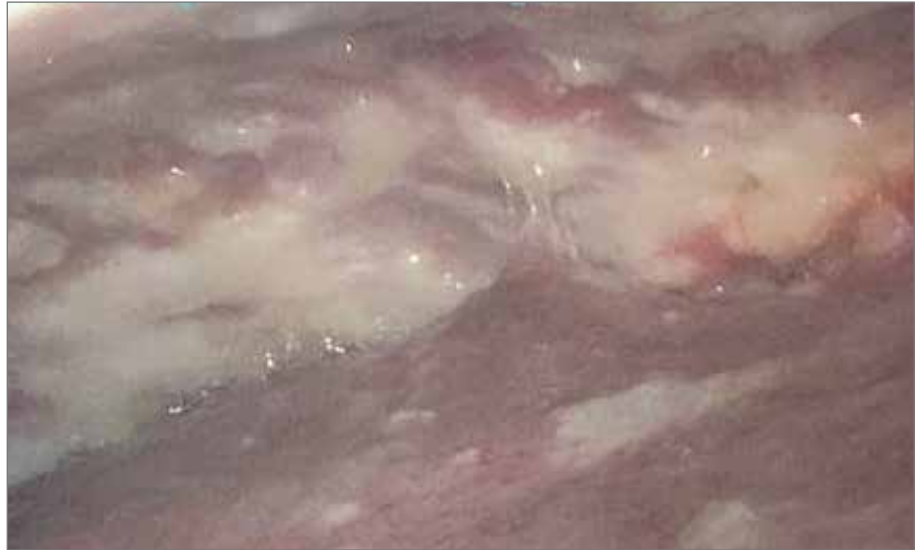Hyperthermic intraperitoneal chemoperfusion (HIPEC) is a unique procedure revolutionizing the treatment of cancers in the abdominal (peritoneal) lining. Offered at only a handful of locations in the United States, including at The Mount Sinai Hospital, the procedure combines surgery with chemotherapy.

The Mount Sinai Hospital was one of the earliest groups to begin using intraperitoneal chemotherapy, commonly used today to treat ovarian cancer. HIPEC is now being used to treat a wide variety of conditions, including peritoneal mesothelioma, appendix and colon cancer, and select cases of gastric cancer.

Responding to the lack of hospitals providing HIPEC, Daniel M. Labow, MD, Chief of the Surgical Oncology Division at The Mount Sinai Hospital, established what is today one of the busiest HIPEC programs in the country. Faculty have performed nearly 334 HIPEC procedures since the program's creation in 2007.

The advantages of HIPEC are vast. The procedure allows for high doses of chemotherapy; enhances and concentrates the chemotherapy within the abdomen; decreases chemotherapy exposure to the rest of the body; improves the rate of chemotherapy absorption, resulting in increased susceptibility of cancer cells; and reduces the typical side effects of chemotherapy.

Before HIPEC is administered, surgeons remove all the visible tumors they can within the peritoneal cavity. This is followed by an internal "bath" of heated chemotherapeutic solution to destroy any remaining



Laparoscopic procedure identifies white nodules/plaque as peritoneal disease

cancer cells, a process known as cytoreductive surgery. HIPEC experts, including Dr. Labow, believe heating the solution improves the absorption of chemotherapy drugs by tumors and destroys microscopic cancer cells that remain in the abdomen after surgery.

HIPEC minimizes the known side effects of chemotherapy that is normally administered intravenously. Additionally, it destroys undetected cancer cells after the tumor has been removed. Perhaps most importantly, however, HIPEC significantly extends patient survival rates. In fact, data from Mount Sinai's HIPEC program show an approximate tripling of the average patient survival rate when compared to patients who used traditional chemotherapy alone. Further studies are being done to build upon these early successes.



**Mount
Sinai**

For you. For life.

Dr. Henry D. Janowitz Division of Gastroenterology
Chief, Bruce E. Sands, MD, MS
 One Gustave L. Levy Place, Box 1069
 New York, NY 10029
 Tel: 212-241-0150
www.icahn.mssm.edu/gastroenterology

Ruth J. & Maxwell Hauser and Harriet & Arthur H. Aufses, Jr., MD, Department of Surgery
Chair, Michael L. Marin, MD
 One Gustave L. Levy Place, Box 1259
 New York, NY 10029
 Tel: 212-241-6591
www.icahn.mssm.edu/surgery

Center for Carcinoid and Neuroendocrine Tumors
 One Gustave L. Levy Place, Box 1041
 New York, NY 10029
 Tel: 212-796-8640
www.mountsinainetcenter.org

Mount Sinai Endoscopy Center
 1184 Fifth Avenue, Seventh Floor
 New York, NY 10029
 Tel: 212-241-6277
www.mountsinai.org/endoscopycenter

The Recanati / Miller Transplantation Institute
 5 East 98th Street, Twelfth Floor
 New York, NY 10029
 Tel: 212-731-RMTI (7684)
www.mountsinai.org/transplant

Mount Sinai Surgical Associates Division of Surgical Oncology (HIPEC Program)
 1470 Madison Avenue, Third Floor
 New York, NY 10029
 Tel: 212-241-2891
www.mountsinai.org/surgicaloncology